

Application of Strain Imaging in Left Ventricular Hypertrophy: Report of 3 Cases and Literature Review

Han-Chung Hsu¹, Chun-I Wu¹, and Wei-Chuan Tsai^{1,2}

¹*Division of Cardiology, Department of Internal Medicine,
Kuo General Hospital, Tainan, Taiwan;*

²*Department of Internal Medicine,
National Cheng University Medical College, Tainan, Taiwan*

Abstract

Left ventricular hypertrophy (LVH) is a common finding from cardiac imaging in daily clinical practice. Presence of LVH is a poor prognostic factor for cardiovascular diseases. Variable reasons caused LVH, including athletes, arterial hypertension, aortic stenosis, hypertrophic cardiomyopathy, and infiltrative heart disease such as cardiac amyloidosis and Fabry disease. Although traditional echocardiography can be used for diagnosis of LVH, quantification of left ventricular mass, and identification of aortic stenosis, it is difficult to differentiate diseases involved in myocardium. Myocardial deformation imaging (strain image) is a new modality by using speckle tracking echocardiography. Strain imaging can be used for better evaluation of LVH. This article reported 3 cases of LVH, addressing roles of strain imaging, and with literature review for the application of strain imaging in evaluation of LVH. (J Intern Med Taiwan 2022; 33: 323-331)

Key Words: Left ventricular hypertrophy; Speckle tracking echocardiography; Strain imaging

Introduction

Left ventricular hypertrophy (LVH) is a common finding from cardiac imaging in daily clinical practice. LVH is present in 15% to 20% of the general population. It is more often seen in blacks, the elderly, the obese, and in patients with hypertension¹. Presence of LVH is a poor prognostic factor for cardiovascular diseases². Variable reasons caused LVH. LVH is commonly detected in athletes following long-term exercise training, in patients with arterial hypertension and aortic steno-

sis (AS) due to persistent pressure overload, and in those with hypertrophic cardiomyopathy (HCM), as well as those with infiltrative diseases such as cardiac amyloidosis, and Fabry disease. Traditional echocardiography can be used for detection of LVH, quantification of left ventricular mass, and identification of underlying etiology, such as AS³. Although traditional echocardiography has a central role in evaluation of LVH, it is difficult to differentiate diseases involved in myocardium. Myocardial deformation imaging (strain image) is a new modality by using speckle tracking echocardiography. Strain

is defined as percentage of changes of myocardial length to the resting length of myocardium during a cardiac cycle. It has been reported that speckle-tracking echocardiographic strain parameters are useful for the detection of early left ventricular structural abnormalities. Strain can be detected from different direction of myocardial deformation including longitudinal, circumferential, and radial directions. Global longitudinal strain (GLS) is reported as a sensitive marker for early subtle abnormalities of LV myocardial performance, helpful for the prediction of outcomes for various cardiac diseases including cardiomyopathies, and superior to conventional echocardiographic indices⁴⁻⁷. GLS is determined as the averaged peak longitudinal strain of 17 LV segments from the three standard apical views and can be assessed as a polar plot in the corresponding segments. GLS is usually $< -19\%$ in normal LV.⁴⁻⁶ The polar plot longitudinal strain mapping (bullseye image) offers an intuitive visual overview of the global and regional LV longitudinal myocardial function, and can be useful in evaluation of LVH.⁸ Here we reported 3 cases of LVH, addressed roles of strain imaging, and reviewed literatures for the application of strain imaging in evaluation of LVH.

Cases report

Case 1

A 79-year-old male came for help due to exertional dyspnea. The patient had mildly elevated blood pressures. The electrocardiography (ECG) showed LVH with strain pattern. Traditional echocardiography showed normal chamber size, normal left ventricular ejection fraction (EF), and concentric LVH especially in apex. The strain bullseye imaging of left ventricle showed decreased longitudinal strain in apical regions with preserved strain in basal left ventricle. Bullseye image showed a typical mapping for apical HCM (Figure 1). GLS decreased to -8.6% indicated the patient had heart failure with preserve ejection fraction (GLS $> -17.5\%$)⁹.

Case 2

A 41-year-old male was noted very high blood pressures (246/160 mmHg) in a routine healthy check-up. The patient denied any discomfort before this visit. ECG also showed LVH with strain pattern. Traditional echocardiography showed markedly concentric LVH with normal left ventricular EF and no AS. The strain bullseye imaging of left ventricle showed decreased longitudinal strain diffusely and lower GLS of -7.6% (Figure 2). Pronounced post-systolic shortening was noted (Figure 3), suggesting LVH due to longstanding uncontrolled hypertension¹⁰.

Case 3

A 53-year-old man came to our clinics due to exertional dyspnea and chest tightness, palpitation, and fainting after squatting. According to the patient's statements, he also had peripheral neuropathy and spinal stenosis which diagnosed in neurology in a different hospital. Due to ECG demonstrating complete right bundle branch block, computed tomography coronary angiography (CTA) was arranged instead of treadmill exercise test for evaluation of coronary artery disease. CTA showed normal coronary arteries but thickened basal septum of left ventricle. Traditional echocardiography showed septal hypertrophy with systolic anterior motion of mitral valve. However, there was no significant pressure gradient across left ventricular outflow tract at rest. Strain bullseye imaging did not show typical apical sparing pattern of cardiac amyloidosis¹¹ but only decreased strain in basal septal area (Figure 4). The myocardial Tc99m-3, 3-diphosphono-1, 2-propanodicarboxylic acid scintigraphy image showed no uptake in the heart. The patient had hypertrophic obstructive cardiomyopathy rather than cardiac amyloidosis. Although pressure gradient across left ventricular outflow tract was not high, dynamic obstruction could occur after squatting in this patient.

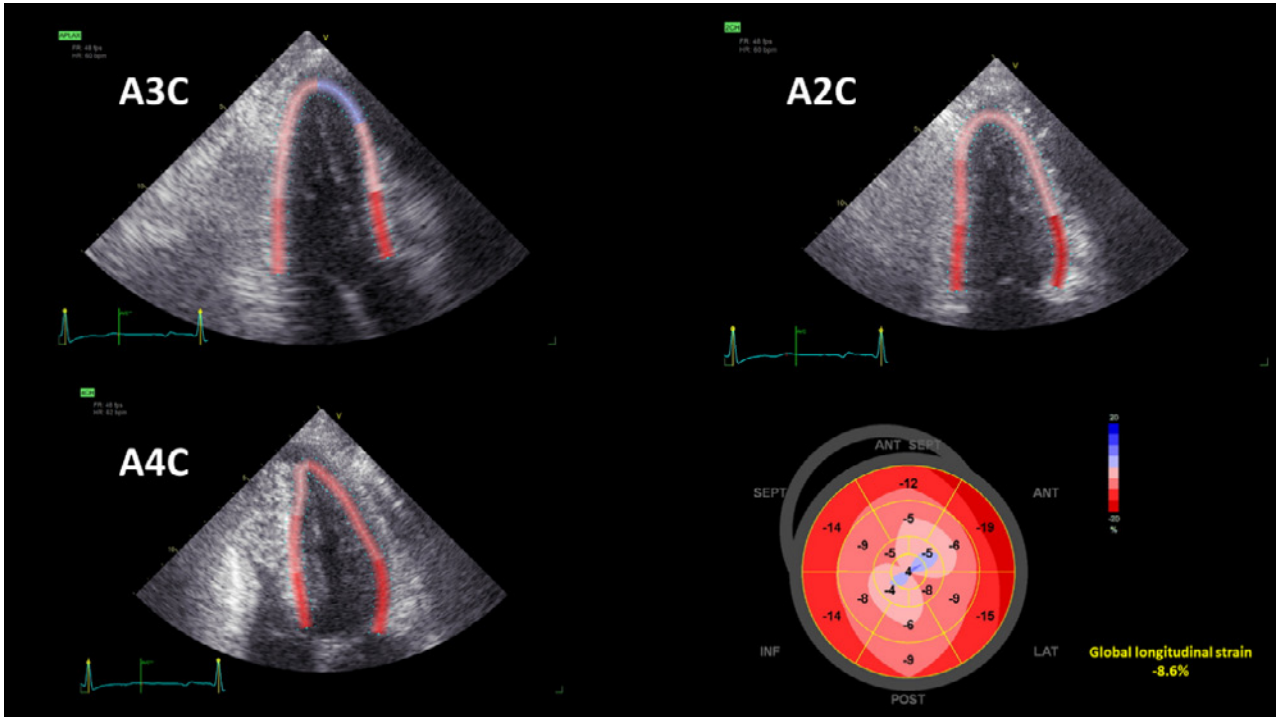


Figure 1. This figure shows 3 apical views with region of interesting on left ventricle myocardium for speckle tracking echocardiography. Bullseye mapping of longitudinal strain in right lower corner shows decreased strain in apical region in Case 1 (A3C = apical 3 chamber view; A4C = apical 4 chamber view; A2C = apical 2 chamber view; ANT SEPT = anteroseptal wall; SEPT = septal wall; INF = inferior wall; POST = posterior wall; LAT = lateral wall; ANT = anterior wall of LV).

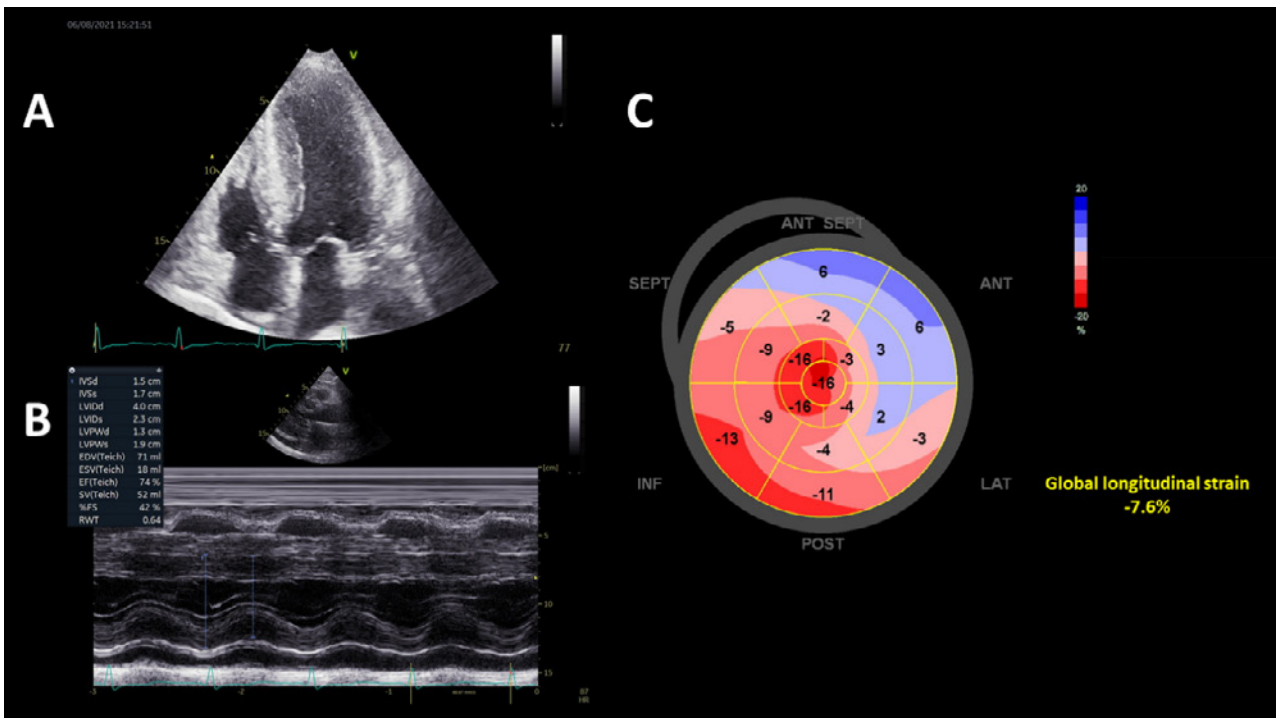


Figure 2. Panel A shows marked left ventricular hypertrophy in apical 4 chamber view. Panel B shows normal ejection fraction in this patient by M-mode. Bullseye mapping of longitudinal strain (panel C) shows diffusely decreased strain in Case 2 (ANT SEPT = anteroseptal wall; SEPT = septal wall; INF = inferior wall; POST = posterior wall; LAT = lateral wall; ANT = anterior wall of LV).

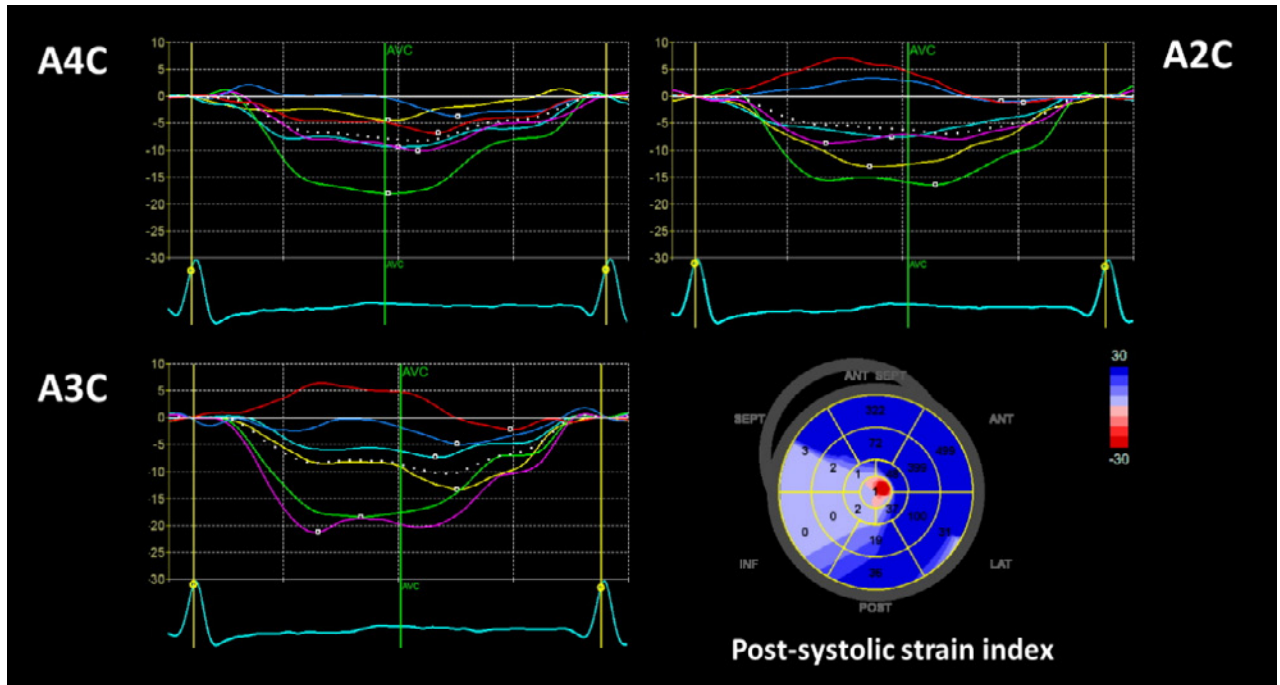


Figure 3. This figure shows strain-time curve of 3 apical views (A3C = apical 3 chamber view; A4C = apical 4 chamber view; A2C = apical 2 chamber view) in 1 cardiac cycle and bullseye mapping of post-systolic strain index. There were several segments of myocardium showing delayed peak-systolic strain after aortic valve closing (AVC) from the strain-time curves. Post-systolic strain index is defined as peak post-systolic longitudinal strain – end-systolic strain / end-systolic strain (%). Bullseye mapping of post-systolic strain index shows markedly increased post-systolic shortening in Case 2. Blue color represents post-systolic shortening.

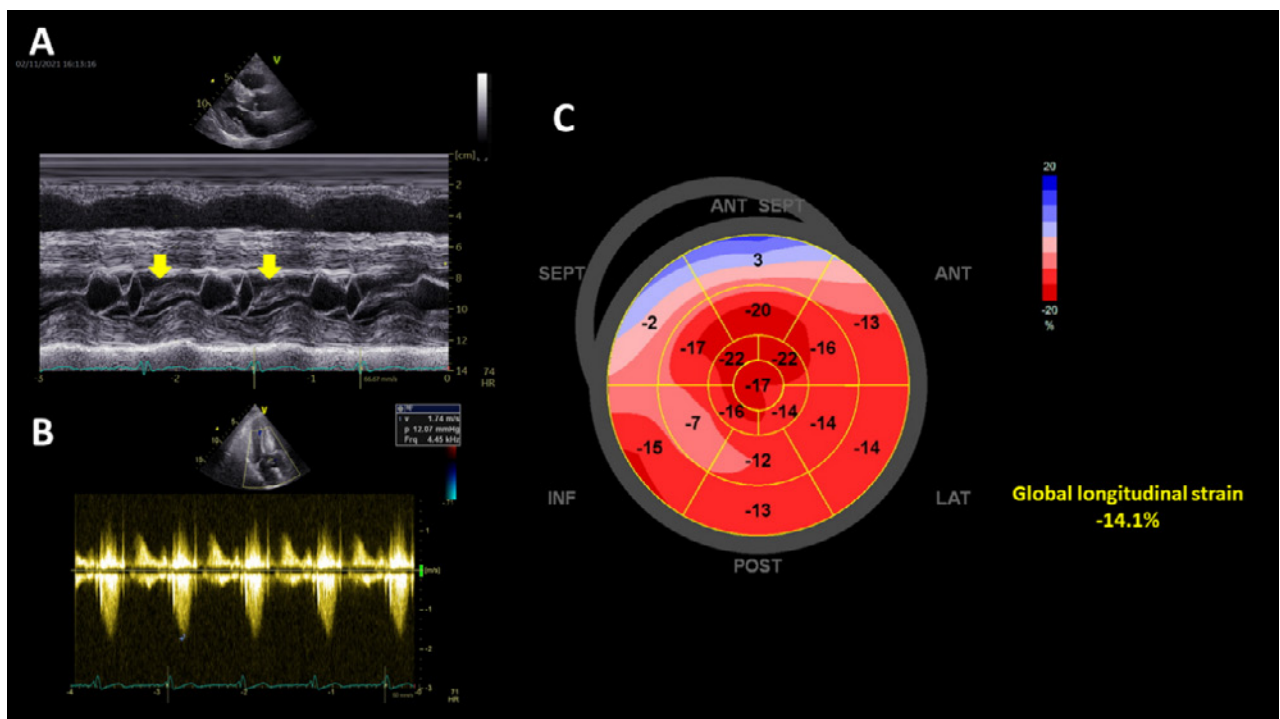


Figure 4. Panel A demonstrates systolic anterior motion of mitral valve (yellow arrow) in M-mode of case 3. Panel B shows no significant resting pressure gradient through left ventricular outflow tract by continuous Doppler. Bullseye mapping of longitudinal strain (panel C) shows decreased strain in basal septum (ANT SEPT = anteroseptal wall; SEPT = septal wall; INF = inferior wall; POST = posterior wall; LAT = lateral wall; ANT = anterior wall of LV). **Global longitudinal strain -14.1%**

Discussion and literature review

Our 3 cases showed the applications of strain bullseye images in evaluation of LVH. LVH is a condition in which there is an increase in left ventricular mass, either due to an increase in wall thickness or due to left ventricular cavity enlargement, or both. Most commonly, the left ventricular wall thickening occurs in response to pressure overload, and chamber dilatation occurs in response to volume overload¹. There are various clinical conditions that can lead to the development of LVH. Table 1 shows the common conditions which caused LVH. Hypertension and AS are the most common causes of LVH. Traditional echocardiography has central role for identifying LVH, and for evaluation of underlying valvular heart diseases included AS. Based on relative wall thickness (RWT) (posterior wall thickness x 2 / left ventricular internal diameter at end-diastole), and the left ventricular mass index (LVMI) (left ventricular mass normalized for body surface area or height), the LVH can be categorized into 2 types; concentric hypertrophy (increased LVMI and RWT more than 0.42) or eccentric hypertrophy (increased LVMI and RWT less than or equal to 0.42). Concentric LVH is an abnormal increase in left ventricular myocardial mass caused by pressure overload induced by chronic hypertension or aortic stenosis. Eccentric LVH is induced by an increased filling pressure of the left ventricle, which represents the underlying mechanism for volumetric or diastolic overload in patients with valvular regurgitation such as aortic or mitral regurgitation as well as in the case of dilated cardiomyopathy. Usefulness of traditional echocardiography is limited in other conditions involved solely myocardium such as hypertrophic and infiltrative cardiomyopathy. Strain imaging can provide additional information for diagnosis in LVH. The applications of strain imaging in the following conditions are introduced in detail.

Arterial hypertension

Hypertension is common in general population. LVH is a relatively early manifestation and a common finding in patients with arterial hypertension⁸. GLS helps to unmask early subclinical left ventricular systolic dysfunction in patients with arterial hypertension⁸. The basal septum is the first segment to undergo changes under the influence of pressure overload, and GLS is further reduced at this site¹². It was previously reported that 46% of patients showed low GLS values (< 17%), and low GLS was associated with long-lasting arterial hypertension and uncontrolled blood pressures for 200 outpatients with arterial hypertension and preserved left ventricular EF¹³. Furthermore, post-systolic shortening was increased in hypertension, our previous study showed degree of post-systolic shortening evaluated by post-systolic strain index (peak post-systolic longitudinal strain – end-systolic strain / end-systolic strain) derived from strain imaging was associated with diastolic dysfunction¹⁰. Case 2 in our report showed decreased GLS (Figure 2)

Table 1. Conditions associated with left ventricular hypertrophy

Conditions
Essential hypertension
Renal artery stenosis
Athletic heart
Aortic valvar stenosis
Coarctation of the aorta
Hypertrophic cardiomyopathy without or with outflow tract obstruction
Subaortic stenosis (left ventricular outflow tract obstruction by muscle or membrane)
Aortic regurgitation
Mitral regurgitation
Dilated cardiomyopathy
Ventricular septal defect
Infiltrative cardiac processes (e.g., Amyloidosis, Fabry disease)

and increased post-systolic strain index (blue area in Figure 3) which indicated the subjects already had occult systolic dysfunction and diastolic dysfunction. Prompt control of hypertension was warranted for this patient. GLS also has a prognostic role in hypertension. Our previous study showed GLS from subepicardial myocardium assessed by layer-specific strain imaging had prognostic role in chronic arterial hypertension¹⁴.

Aortic stenosis

AS is a growing health problem and frequently associated with LVH. Patients with severe AS and preserved left ventricular EF had lower GLS compared with matched control subjects, and that this difference was more pronounced in the basal LV segments¹⁵. A lower GLS was also found to be associated with a higher LVMI and RWT, which supports the notion of a direct connection between concentric remodeling and contractile dysfunction¹⁵. Layer-specific strain imaging is also helpful for evaluation of hypertrophied myocardium in AS. Our previous study showed strain difference (strain gradient) between subendocardial and subepicardial myocardium was correlated with left ventricular EF and hemodynamic profile. Strain gradient is defined as absolute value of global subendocardial strain – global subepicardial strain using layer-specific strain measurements¹⁶. Strain gradient was preserved in AS and helpful to distinguish between AS and HCM¹⁶.

Hypertrophic cardiomyopathy

HCM is the most common genetically determined cardiomyopathy in adults. The hypertrophy can be asymmetric in septum, in apex, and other distribution. It has been reported that LV longitudinal myocardial function is reduced even though EF is normal and may become abnormal before wall thickness starts to increase¹⁷. LV longitudinal myocardial function is typically reduced at the site of

hypertrophy. Our case 1 showed decreased longitudinal strain in apex (Figure 1) indicative of apical HCM, and case 3 showed decreased longitudinal strain in basal septum (Figure 4) which is typical for hypertrophic obstructive cardiomyopathy. Moreover, abnormal GLS was found to be a better predictor of outcome for HCM than conventional echocardiographic parameters¹⁸.

Cardiac amyloidosis

Cardiac involvement occurs in up to 50% of patients with primary amyloidosis and indicates almost invariably a grave prognosis. Conventional echocardiographic features associated with cardiac amyloidosis include concentric LVH and right ventricular hypertrophy, normal LV cavity size, dilated atria, and pericardial effusion.

LV diastolic abnormalities are generally recognized as the earliest manifestation of cardiac amyloidosis, while LV global systolic function remains normal until the later stages of the disease^{8,19}. The myocardial texture often features a distinct “granular sparkling” appearance, and this echocardiographic feature is well known as a clue in the diagnosis of cardiac amyloidosis²⁰. However, other conditions also had the same pattern, and its sensitivity and specificity were questionable, especially with newer echocardiographic image processing techniques which would reduce sparkles in myocardium^{8,21}. It is noteworthy that cardiac amyloidosis is characterized by regional variations in longitudinal strain from base to apex. A longitudinal strain gradient with preserved systolic strain at apical segments and significantly reduced systolic strain at mid and basal segments is consistently observed, this manifestation could be demonstrated as “Apical Sparing” pattern in bullseye mapping and suited to differentiate patients with cardiac amyloidosis from patients with other causes of LVH²². Apical sparing pattern demonstrates not only preserved strain of apical segments but also markedly decreased strain

in mid and basal segments. A relative apical longitudinal strain of 1.0, determined by using the equation [average apical longitudinal strain/(average basal-longitudinal strain + mid-longitudinal strain)], was associated with a sensitivity of 93% and specificity of 82% for differentiating patients with cardiac amyloidosis from control patients with LVH with an area under the curve of 0.94²². In our case 3, although some red flags existed, bullseye mapping did not show typical apical sparing pattern. Myocardial Tc99m-3, 3-diphosphono-1, 2-propanodicarboxylic acid scintigraphy image confirmed that the patient did not have amyloidosis deposition. Furthermore, previous study also showed GLS could be an independent predictor for outcome in cardiac amyloidosis²³.

Fabry disease

Fabry disease is an X-linked lysosomal storage disorder caused by α -galactosidase A deficiency. The clinical presentation is multi-systemic, affecting the kidneys, heart, and nervous system. Cardiac pathophysiology is characterized by globotriaosylceramide accumulation within cardiomyocytes that cause LVH with subsequent myocardial replacement fibrosis. The use of the binary sign or endocardial stripe has been investigated as a hallmark of Fabry disease. The binary sign is the appearance of a bright, hyperechogenic region in the LV myo-

cardium adjacent to a relatively low echo intensity region with a clear black and white interface⁸. However, previous studies showed binary sign presented rarely in Fabry disease, and the diagnostic value was limited^{24,25}. Strain imaging can be helpful for diagnosis of Fabry disease. The development of fibrosis is often localized in the basal posterior-lateral wall and reduced longitudinal strain in the basal lateral wall was found at the very early stages of Fabry disease^{26,27}.

Athlete heart

Physiological hypertrophy can be detected in the heart of athletes, whose LV dilation and LVH may be pronounced enough to mimic a pathological state, but LV systolic and diastolic function is normal or even supernormal⁸. Identification of underlying cardiomyopathies can be challenging in the athletes when the wall thickness is between 12 and 16 mm (the so-called gray zone of LVH). Previous studies showed GLS was preserved in athletes with LVH but was decreased in HCM^{28,29}. Strain imaging can be helpful for differentiating athletes LVH from HCM.

Conclusions

Our case reports showed the usefulness of strain imaging in evaluation of LVH. Table 2 shows a summary of major findings from strain imaging

Table 2. Strain pattern in different conditions of left ventricular hypertrophy

Condition	Global longitudinal strain	Bullseye mapping
Arterial hypertension	Preserved or reduced	1. Basal septum or diffused ^{8,10,13} 2. Increased post-systolic strain ¹⁰
Aortic stenosis	Reduced	1. Basal left ventricular segments ^{8,15} 2. Decreased subendocardial to subepicardial strain gradient in severe case ¹⁶
Hypertrophic cardiomyopathy	Reduced	The sites of hypertrophy, apex in apical hypertrophy, and basal septum in outlet hypertrophy ^{17,18}
Cardiac amyloidosis	Reduced	Apical sparing pattern ²²
Fabry disease	Reduced	Basal posterior-lateral walls ²⁷
Athlete heart	Preserved	None ^{28,29}

in different LVH conditions. Strain imaging with detection of a disease-related typical deformation pattern and bullseye longitudinal strain mapping may provide valuable clues for the final diagnosis in some patients with unclear LVH. The GLS also has prognostic role in some forms of LVH.

Funding/Support statement

This study was supported in part by Grant 110-14 from Kuo General Hospital, Tainan, Taiwan.

References

- Cuspidi C, Sala C, Negri F, et al., Italian Society of Hypertension. Prevalence of left-ventricular hypertrophy in hypertension: an updated review of echocardiographic studies. *J Hum Hypertens* 2012;26:343-9.
- Verdecchia P, Carini G, Circo A, et al. Left ventricular mass and cardiovascular morbidity in essential hypertension: the MAVI study. *J Am Coll Cardiol* 2001;38:1829-35.
- Weidemann F, Niemann M, Ertl G, et al. The different faces of echocardiographic left ventricular hypertrophy: clues to the etiology. *J Am Soc Echocardiogr* 2010;23:793-801.
- Tanaka H. Utility of strain imaging in conjunction with heart failure stage classification for heart failure patient management. *J Echocardiogr* 2019;17:17-24.
- Gorcsan J 3rd, Tanaka H. Echocardiographic assessment of myocardial strain. *J Am Coll Cardiol* 2011;58:1401-13.
- Stanton T, Leano R, Marwick TH. Prediction of all-cause mortality from global longitudinal speckle strain: comparison with ejection fraction and wall motion scoring. *Circ Cardiovasc Imaging* 2009;2:356-64.
- Sung JM, Su CT, Chang YT, et al. Independent value of cardiac troponin T and left ventricular global longitudinal strain in predicting all-cause mortality among stable hemodialysis patients with preserved left ventricular ejection fraction. *Biomed Res Int* 2014;2014:217290.
- Tanaka H. Efficacy of echocardiography for differential diagnosis of left ventricular hypertrophy: special focus on speckle-tracking longitudinal strain. *J Echocardiogr* 2021; 19:71-79.
- Liu YW, Tsai WC, Su CT, et al. Evidence of left ventricular systolic dysfunction detected by automated function imaging in patients with heart failure and preserved left ventricular ejection fraction. *J Card Fail* 2009;15:782-9.
- Tsai WC, Liu YW, Chen JY, et al. Postsystolic strain index is associated with delayed diastolic lengthening and diastolic dysfunction of the left ventricle in untreated hypertension. *J Hypertens* 2012;30:787-93.
- Martinez-Naharro A, Baksi AJ, Hawkins PN, et al. Diagnostic imaging of cardiac amyloidosis. *Nature Rev Cardiol* 2020;17:413-26.
- Galderisi M, Lomoriello VS, Santoro A, et al. Differences of myocardial systolic deformation and correlates of diastolic function in competitive rowers and young hypertensives: a speckle tracking echocardiography study. *J Am Soc Echocardiogr* 2010;23:1190-8.
- Bendiab STN, Meziane-Tani A, Ouabdesselam S, et al. Factors associated with global longitudinal strain decline in hypertensive patients with normal left ventricular ejection fraction. *Eur J Prev Cardiol* 2017;24:1463-72.
- Lee WH, Liu YW, Yang LT, et al. Prognostic value of longitudinal strain of subepicardial myocardium in patients with hypertension. *J Hypertens* 2016;34:1195-200.
- Lafitte S, Perlant M, Reant P, et al. Impact of impaired myocardial deformations on exercise tolerance and prognosis in patients with asymptomatic aortic stenosis. *Eur J Echocardiogr* 2009;10:414-9.
- Huang MS, Lee WH, Tsai HR, et al. Value of layer-specific strain distribution patterns in hypertrophied myocardium from different etiologies. *Int J Cardiol* 2019;281:69-75.
- Losi MA, Nistri S, Galderisi M, et al. Echocardiography in patients with hypertrophic cardiomyopathy: usefulness of old and new techniques in the diagnosis and pathophysiological assessment. *Cardiovasc Ultrasound* 2010;8:7.
- Reant P, Mirabel M, Lloyd G, et al. Global longitudinal strain is associated with heart failure outcomes in hypertrophic cardiomyopathy. *Heart* 2016;102:741-7.
- Klein AL, Hatle LK, Taliereio CP, et al. Serial Doppler echocardiographic follow-up of left ventricular diastolic function in cardiac amyloidosis. *J Am Coll Cardiol* 1990;16:1135-41.
- Siqueira-Filho AG, Cunha CL, Tajik AJ, et al. M-mode and two dimensional echocardiographic features in cardiac amyloidosis. *Circulation* 1981;63:188-96.
- Selvanayagam JB, Hawkins PN, Paul B, et al. Evaluation and management of the cardiac amyloidosis. *J Am Coll Cardiol* 2007;50:2101-10.
- Phelan D, Collier P, Thavendiranathan P, et al. Relative apical sparing of longitudinal strain using two-dimensional speckle tracking echocardiography is both sensitive and specific for the diagnosis of cardiac amyloidosis. *Heart* 2012; 98:1442-8.
- Barros-Gomes S, Williams B, Nhola LF, et al. Prognosis of light chain amyloidosis with preserved LVEF: added value of 2D speckle-tracking echocardiography to the current prognostic staging system. *JACC Cardiovasc Imaging* 2017;10: 398-407.
- Kounas S, Demetrescu C, Pantazis AA, et al. The binary endocardial appearance is a poor discriminator of Anderson-Fabry disease from familial hypertrophic cardiomyopathy. *J Am Coll Cardiol* 2008;51:2058-61.
- Mundigler G, Gaggli M, Heinze G, et al. The endocardial binary appearance ("binary sign") is an unreliable marker for echocardiographic detection of Fabry disease in patients with left ventricular hypertrophy. *Eur J Echocardiogr* 2011; 12:744-9.
- Weidemann F, Breunig F, Beer M, et al. The variation of morphological and functional cardiac manifestation in Fabry disease: potential implications for the time course of the disease. *Eur Heart J* 2005;26:1221-7.

27. Kramer J, Niemann M, Liu D, et al. Two-dimensional speckle tracking as a non-invasive tool for identification of myocardial fibrosis in Fabry disease. *Eur Heart J* 2013;34:1587-96.
28. Kansal MM, Lester SJ, Surapaneni P, et al. Usefulness of two dimensional and speckle tracking echocardiography in “Gray Zone” left ventricular hypertrophy to differentiate professional football player’s heart from hypertrophic cardiomyopathy. *Am J Cardiol* 2011;108:1322-6.
29. Afonso L, Kondur A, Simegn M, et al. Two-dimensional strain profiles in patients with physiological and pathological hypertrophy and preserved left ventricular systolic function: a comparative analyses. *BMJ Open* 2012;17(2):e001390.

應變造影於評估左心室肥厚的應用： 三個病例報告與文獻回顧

徐漢仲¹ 吳俊毅¹ 蔡惟全^{1,2}

¹台南郭綜合醫院 心臟內科

²台南國立成功大學醫學院 內科學科

摘 要

左心室肥厚是一個臨床上經由心臟造影常被發現的問題。有左心室肥厚代表心血管疾病的預後較差。左心室肥厚常見的原因包括運動員、高血壓、主動脈瓣狹窄、肥厚性心肌病變，浸潤性心臟病如類澱粉質沉積、法布瑞氏症等。傳統心臟超音波可以用來確定左心室肥厚、定量肥厚程度、評估是否有主動脈瓣狹窄等，但對於直接侵犯心肌的疾病比較難區分。心肌形變造影(應變造影)是一種運用亮點追蹤心臟超音波的方法，可以用來更好的評估左心室肥厚。這裡我們報告三個左心室肥厚的病例探討應變心臟超音波的運用，並做有關應變心臟超音波於常見左心室肥厚情況下的臨床運用。