

# Migratory Toothpick Liver Abscess as A Rare Complication of Guts Foreign Body Penetration: A Case Report and Literature Review

Yu-Chi Tsai<sup>2</sup>, and Chien-Wei Huang<sup>1,2,3</sup>

<sup>1</sup>*Division of Gastroenterology, <sup>2</sup>Department of Internal Medicine, Kaohsiung Armed Forces General Hospital, Kaohsiung City, Taiwan;*  
<sup>3</sup>*Department of Nursing, Tajen University, Kaohsiung City, Taiwan*

## Abstract

Migratory foreign body liver abscess is a rare presentation of all cases of guts ingestion of foreign bodies. Different pathogenic mechanisms make it unique among the general population of liver abscess. Fever and abdominal pain are typical reported symptoms; however, most patients cannot remember the ingestion event. Foreign body removal and adequate infection control are the fundamental treatments. We report a case of migratory foreign body liver abscess which was successfully cured by endoscopic removal of a toothpick in the stomach. (J Intern Med Taiwan 2022; 33: 64-69)

**Key Words:** Liver abscess, Foreign body, Toothpick

## Background

Migratory foreign body liver abscess is a rare presentation among all cases of guts ingestion of foreign bodies. Due to different pathogenic mechanisms from among the general population of liver abscess, migratory foreign body liver abscess has unique clinical manifestations. Fever and abdominal pain are the typical symptoms; however, most patients cannot remember the ingestion event which led to the challenging diagnosis. Foreign body removal and adequate infection control are the fundamental treatments. We report a case of migratory foreign body liver abscess. The abdominal computed tomography (CT) disclosed a linear opacity penetra-

tion from the stomach to the liver with concomitant abscess formation in the left lobe. The patient was successfully cured by endoscopic removal of the toothpick along with antibiotics treatment.

## Case report

A 59-year-old man presented himself in our emergency department with a 3-week history of epigastric pain and 10-day history of poor appetite. The illness attacked him on and off, associated with drenching night sweats and fever starting one week ago. His pain was not relieved after taking pain killers and was not related to positional change. The patient has smoked cigarettes since he was 26-years-old and infrequently drank alcohol. He was a bus

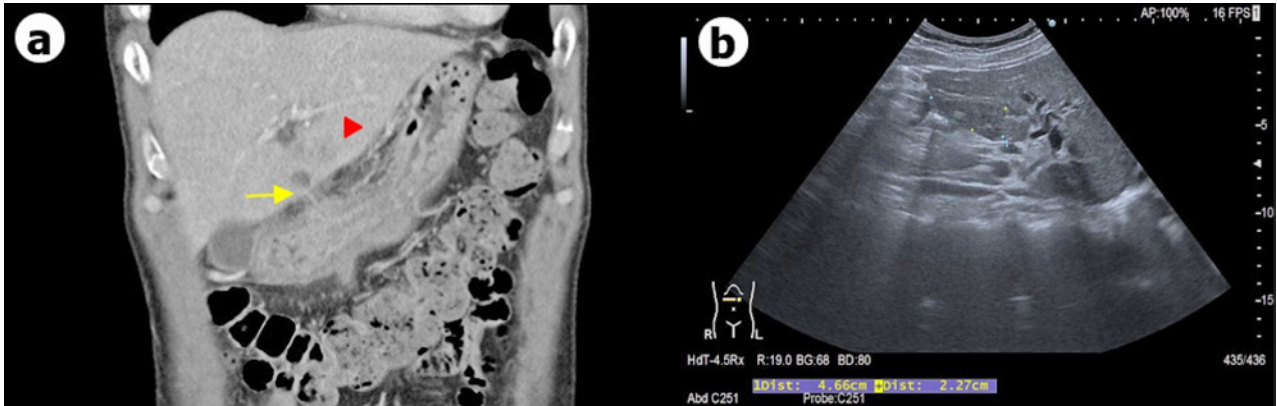


Figure 1. (a) Abdominal computed tomography revealed a linear high density opacity (40 mm in length, yellow arrow) at the lesser curvature side of body portion of stomach to the segment 4 of liver. Low attenuation surround the opacity was noted (red triangle), which consider liver abscess caused by migratory foreign body from stomach perforation. (b). Abdominal ultrasonography disclosed an ill focal hypo-echoic area, measured  $4.7 \times 2.3$  cm, over the segment 4 of liver. Liver abscess was favored as image diagnosis.

driver as his usual state before this episode. Type 2 diabetes mellitus had been diagnosed one year earlier without regular follow up visits for personal reasons.

The physical examinations showed soft abdomen with tenderness over the epigastrium. The patient looked tired and uncomfortable. The temperature was  $37.7^{\circ}\text{C}$ , blood pressure 142/82 mm Hg, heart rate 106 beats per minute, and respiratory rate 19 breaths per minute. An abdominal CT revealed a linear high-density opacity at the lesser curvature side of the body portion of the stomach to the segment 4 of the liver with an area of low attenuation (Figure 1).

The hemogram disclosed leukocytosis with neutrophil predominant. Blood levels of electrolytes, glucose, liver, and renal functions were normal. The other laboratory results are shown in Table 1.

Treatment with ceftriaxone was begun after blood cultures were obtained. The abdominal ultrasonography revealed one focal hypoechoic area over the segment 4 of the liver. The esophagogastroduodenoscopy was performed and one wooden toothpick was found in the stomach. Endoscopic removal of the foreign body was completed by snare (Figure 2). The blood culture yielded

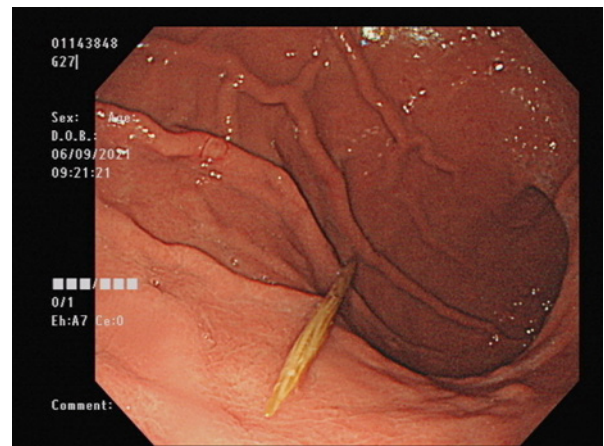


Figure 2. Esophagogastroduodenoscopy found a wooden toothpick retained in the stomach. The toothpick was removed by snare.

*Streptococcus intermedius*. In the second week of admission, fever and abdominal pain subsided. The patient was discharged to complete 6 weeks of oral antibiotic treatment. At a clinic visit 3 months into treatment, the patient felt much better and his sequential abdominal ultrasonography revealed disease resolution. We asked if the patient remembered when or how a toothpick was ingested and he could not recall it accurately. Liver abscess due to toothpick penetration from stomach was favored as the final diagnosis.

Table 1. Laboratory results

Variable	Reference range	Illness day 24, On presentation	Illness day 35, On discharge
Hemoglobin (g/dL)	12-15.5	12.2	11.9
Hematocrit (%)	34.9-44.5	37.0	37.7
White-cell count (per mm <sup>3</sup> )	4000-11000	20090	5160
Differential count (%)			
Neutrophils	40-70	87.4	73.5
Lymphocytes	22-44	7.9	18.7
Monocytes	4-11	3.8	5.1
Platelet count (*10 <sup>3</sup> per mm <sup>3</sup> )	135-400	549	519
Mean corpuscular volume (fl)	80.0-100.0	90.9	91.7
C-reactive protein (mg/dL)	<0.5	21.30	1.54
Sodium (mmol/liter)	136-145	134	138
Potassium (mmol/liter)	3.5-5.2	3.9	4.5
Urea nitrogen (mg/dL)	8-25	18	12
Creatinine (mg/dL)	<1.0	1.0	0.6
Estimated glomerular filtration rate (ml/min/1.73 m <sup>2</sup> )	>60	81.0	146.1
Glucose (mg/dL)	70-110	106	122
Aspartate aminotransferase (U/liter)	≤33	15	13
Alanine aminotransferase (U/liter)	10-49	27	17
Total bilirubin (mg/dL)	0.3-1.2	0.57	
Hemoglobin A1c (%)	<5.7	6.6	
Specimen			
Blood culture	negative	<i>Streptococcus intermedius</i>	

## Discussion

Liver abscess is the most common type of visceral abscess<sup>1</sup>. In Taiwan, the annual incidence of liver abscess is estimated as 13.52<sup>2</sup> to 17.59<sup>3</sup> cases per 100,000 people, which is higher than that in Western countries<sup>4</sup>. Certain conditions are considered risk factors, including: diabetes mellitus, underlying hepatobiliary or pancreatic disease, cirrhosis, immunocompromised, and chronic use of proton-pump inhibitor<sup>5</sup>. Diabetic patients diagnosed with liver abscesses are frequently infected with *Klebsiella pneumoniae*. Poor glycemic control impairs

neutrophil phagocytosis of *Klebsiella pneumoniae*. It is therefore necessary to control blood sugar<sup>6</sup>.

A secondary cause usually contributes to patients suffering from liver abscess. The pathogenesis can be caused by pathoorganisms spreading from the bloodstream, the nearby biliary tract, or rarely, resulting from direct iatrogenic or penetrating trauma, such as surgical procedures or foreign body migration<sup>5</sup>.

Foreign body ingestion is usually accidental and passes smoothly with only 1% of the cases leading to perforation in adults<sup>7</sup>. Fish bone, toothpick and chicken bone are the most frequently reported

foreign objects<sup>8</sup>. While sharp-pointed items have higher rates of bowel perforation, old age, underlying psychiatric diseases, alcohol or illicit drug use, are also risk factors of serious complications<sup>7</sup>. All guts segments tend to be similar regarding prevalence, however, the area of angulations and underlying structure abnormalities may increase the risk of luminal obstruction or perforation<sup>7</sup>.

For liver abscesses, foreign body migrates from the guts and eventually perforates the liver causing 1-5% of all cases<sup>9</sup>. Due to the structural contraction of the pyloric sphincter and the subsequent narrowing of the lumen, the gastric pylorus and duodenum are the most common locations of perforation<sup>10,11</sup>. Given the proximity of the anatomical location, perforation of the stomach usually causes left lobe liver abscess<sup>10-12</sup>. This is also considered a clue of migratory foreign body liver abscess because in general, liver abscesses usually occur in the right lobe of the liver rather than the left lobe due to the pathoorganism bringing perfusion of the hepatic portal blood flow<sup>10,11</sup>.

Fever and abdominal pain are the most reported clinical presentations of migrated foreign body liver abscess<sup>10,12</sup>. A history of documented psychiatric illness and foreign body ingestion may be suggestive<sup>11,12</sup>. Most patients have non-specific symptoms and cannot recall the ingestion episode<sup>8,12</sup>. Both the abdominal ultrasonography and CT are useful diagnostic tools<sup>8,10</sup>. The ultrasonography is convenient and aids physician in assisting treatment response. The CT is the first choice of imaging exam because of its better resolution and accuracy<sup>10,12</sup>. The endoscopy and laparotomy are invasive but therapeutic, and may be the only diagnostic tool when the above-mentioned examinations fail<sup>10,11</sup>.

Liver abscesses located in the left lobe or unusual locations, lack of risk factors such as diabetes, treatment failure, or evidence of foreign body or fistula formation on imaging may be evidence of

foreign body liver abscess and require performing upper gastrointestinal endoscopy<sup>12</sup>.

Part of the liver abscess without evident etiology may be related to occult colorectal cancer because colon cancer or polyps damage the mucosal barrier of the intestinal wall, leading to pathogen invasion through the bloodstream and the development of liver abscess. For patients with unexplained liver abscess, a history of diabetes, and the presence of *Klebsiella pneumoniae* in bacteriological culture, colonoscopy should be arranged to check whether there is coexistence of colon cancer<sup>13</sup>.

The pathoorganisms of migratory foreign body liver abscess are usually normal flora of human oral cavity, such as *Streptococcus* species<sup>8,10</sup>. This differs from the previously reported main pathogenic strains of liver abscesses, such as *Escherichia coli* and *Klebsiella pneumoniae*. Clinicians should pay attention and consider foreign body retention as an occult culprit when an unusual strain is isolated from a patient diagnosed with liver abscesses<sup>11</sup>.

Early removal of the foreign bodies, assisting abscess drainage, and the administration of adequate antibiotics are the cornerstones of treatment for migratory foreign body liver abscess. For most patients with foreign body present in the intestine, and lack of emergent surgical characteristics such as pneumoperitonium, bile leakage, or vascular damage; endoscopic foreign body intervention can be considered<sup>10,14</sup>. Small (<3 cm), or uni-lobulated liver abscess can be drained initially<sup>15</sup>. Surgical intervention may be preserved for patients with large, multi-lobulated abscesses, ruptured lesions, or failed multiple attempts at image-guided therapy<sup>5,15</sup>.

The overall prognosis is determined on rapid and accurate diagnosis<sup>10</sup>. It is also suggested that in cases of liver abscess with unexplained etiology or treatment failure, migratory foreign body may be a clinically important differential diagnosis<sup>8,10,12</sup>.

## Conclusion

Migratory foreign body liver abscess is a rare presentation of all cases of liver abscess. Because of the anatomical characteristics, the stomach and duodenum are the most common locations for perforation, and the left lobe of the liver has higher frequency of abscess formation. The diagnostic choices of images are abdominal CT and ultrasonography. The endoscopy and laparotomy are more invasive but suitable for selected patients.

The most frequent isolated pathoorganisms of migratory foreign body liver abscess are normal flora of human oral cavity, which is quite different from the general group of liver abscesses. Unusual locations, uncommon strains, and liver abscesses that have failed treatment all indicate the possibility of foreign body as the hidden culprit. Early removal of the foreign body, assisting abscess drainage, and adequate antibiotics administrations are the principles of the treatment for migratory foreign body liver abscess. Precise and prompt diagnosis is the key for a better outcome.

## Conflicts of Interests

The authors declare no conflicts of interest.

## Funding Statement

This research did not receive any specific grants from funding agencies in the public, commercial, and non-profit sectors.

## References

1. Altemeier WA, Culbertson WR, Fullen WD, Shook CD. Intra-abdominal abscesses. *Am J Surg* 1973;125:70-9.
2. Chen YC, Lin CH, Chang SN, Shi ZY. Epidemiology and clinical outcome of pyogenic liver abscess: an analysis from the National Health Insurance Research Database of Taiwan, 2000-2011. *J Microbiol Immunol Infect* 2016;49:646-53.
3. Tsai FC, Huang YT, Chang LY, Wang JT. Pyogenic liver abscess as endemic disease, Taiwan. *Emerg Infect Dis* 2008;14:1592-600.
4. Kaplan GG, Gregson DB, Laupland KB. Population-based study of the epidemiology of and the risk factors for pyogenic liver abscess. *Clin Gastroenterol Hepatol* 2004;2:1032-8.
5. Mavilia MG, Molina M, Wu GY. The evolving nature of hepatic abscess: A review. *J Clin Transl Hepatol* 2016;4:158-68.
6. Wang JH, Liu YC, Lee SS, et al. Primary liver abscess due to *Klebsiella pneumoniae* in Taiwan. *Clin Infect Dis* 1998;26:1434-8.
7. Vizcarrondo FJ, Brady PG, Nord HJ. Foreign bodies of the upper gastrointestinal tract. *Gastrointest Endosc* 1983;29:208-10.
8. Santos SA, Alberto SC, Cruz E, et al. Hepatic abscess induced by foreign body: Case report and literature review. *World J Gastroenterol* 2007;13:1466-70.
9. Saborido BP, Cuadrado MB, López RV. A liver abscess secondary to a toothpick: A rare complication of accidental foreign body ingestion. *Rev Esp Enferm Dig* 2019;111:167-8.
10. Chong LW, Sun CK, Wu CC, Sun CK. Successful treatment of liver abscess secondary to foreign body penetration of the alimentary tract: A case report and literature review. *World J Gastroenterol* 2014;20:3703-11.
11. Martin S, Petraszko AM, Tandon YK. A case of liver abscesses and porto-enteric fistula caused by an ingested toothpick: A review of the distinctive clinical and imaging features. *Radiol Case Rep* 2020;15:273-6.
12. Leggieri N, Marques-Vidal P, Cerwenka H, et al. Migrated foreign body liver abscess: Illustrative case report, systematic review, and proposed diagnostic algorithm. *Medicine (Baltimore)* 2010;89:85-95.
13. Jeong SW, Jang JY, Lee TH, et al. Cryptogenic pyogenic liver abscess as the herald of colon cancer. *J Gastroenterol Hepatol* 2012;27:248-55.
14. Steinbach C, Stockmann M, Jara M, Bednarsch J, Lock JF. Accidentally ingested toothpicks causing severe gastrointestinal injury: A practical guideline for diagnosis and therapy based on 136 case reports. *World J Surg* 2014;38:371-7.
15. Hope WW, Vrochides DV, Newcomb WL, Mayo-Smith WW, Iannitti DA. Optimal treatment of hepatic abscess. *Am Surg* 2008;74:178-82.

# 遊走性異物造成腸胃道穿孔併發肝膿瘍： 病例報告與文獻回顧

蔡諭奇<sup>1</sup> 黃健維<sup>1,2,3</sup>

國軍高雄總醫院 <sup>1</sup>內科部 <sup>2</sup>肝膽腸胃科  
<sup>3</sup>大仁科技大學護理部

## 摘 要

遊走性異物造成的肝膿瘍是所有腸胃道異物中的罕見病例表現。由於具不同的發病機制，使此一類型之肝膿瘍不同於一般肝膿瘍之族群。發燒和腹痛是典型的報告症狀，然而，大多數患者並不記得異物攝入事件。移除異物和充分控制感染是治療的根本辦法。我們報導了一例遊走性異物造成之肝膿腫，而後經內視鏡移除胃內牙籤並成功治癒之案例。